

## Effects of Aronia Melanocarpa on the Process of Thymic Involution in Aging Rats

*E. Daskalova\**, *S. Delchev\**, *D. Staribratova\*\**

*\*Department of Anatomy, Histology and Embryology, Medical University, Plovdiv*

*\*\*Department of Pathology, Medical University, Plovdiv*

Progressive thymic involution, a sign of aging leads to loss of immune function associated with T-cell immunity and increased susceptibility to infections, risk for development of autoimmune diseases and neoplasms in adults. It has been shown that the thymic tissue is a plastic tissue and the process of involution can be delayed and even therapeutically reversed. The use of antioxidants is one potential therapeutic approach for slowing aging of immunity. The purpose of this study is to determine the effect of Aronia melanocarpa juice either pure or enriched with 1% pectin on the thymus involution in aging rats. The results show differences in thymus weight index, weight and size between the groups of treated rats and normal controls. The thymus of treated animals along with the usual age-related changes shows increased cortical apoptosis similar to the extent seen in young controls and is suggested as an expression of remodeling or even rejuvenating.

*Key words:* Thymic involution, Antioxidants, Aronia melanocarpa.

### Introduction

One of the most significant changes occurring in the process of normal aging is immune aging affecting all the cells and organs of innate and acquired immunity. Progressive thymic involution, a definite sign of aging, leading to loss of immune functions associated with T-cell-mediated immunity is generally associated with increased susceptibility to infections as well as increase in risk of autoimmune diseases and neoplasms in adults [8]. There is a growing evidence that the thymus tissue is plastic and that the process of involution can be therapeutically influenced and even reversed [6, 7]. At present, there are several potential therapeutic approaches for slowing aging of immunity, including the use of antioxidants [2]. The morphological changes occurring in the involuting rat thymus are similar to those in humans, and as such rats are an appropriate model for studying the process of immune senescence [9]. The anthocyanin fruit Aronia melanocarpa is ranked first in its antioxidant potential as confirmed by several different methods. A number of in vitro and in vivo studies have demonstrated the wide range of applications of the juice extracts or the dry substance of the fruits of Aronia melanocarpa, as anti-mutagenic, anti-cancer, lipid-lowering, antidiabetic, antihyperten-

sive, hepatoprotective, immunomodulatory effects etc. [3]. The literature provides only limited data on the effect of its application on aging and in particular on age related involution of the thymus. The purpose of this study is to determine the influence of Aronia melanocarpa as pure juice or in combination with pectin on thymic involution in rats.

## Materials and Methods

Fruit juices of Aronia melanocarpa – pure and enriched with 1% pectin were provided by “VITANEA-Ltd”, Plovdiv and were stored at 6 °C. Total content of anthocyanins in the first was 305.6 mg/l, in the second 598.5 mg/l, and the polyphenol content was respectively 5069.3 mg/l and 2571 mg/l, as reported from the assays performed in LBAV (Laboratory of biologically active substances) affiliation of Bulgarian Academy of Science. The study included 24 male Wistar rats, 18 of them at the age of 10 months with initial body weight  $350\text{g} \pm 50$ ; 6 animals of 2 months of age and body weight  $100 \pm 10$ . Animals were provided by and bred in the vivarium of the Medical University in Plovdiv under standard laboratory conditions. The rats were divided into 4 groups: two control groups – the one defined as young (Cy) – 2-month-old, and the other as old (Co) - 10-month-old, which had been put on a standard diet and tap water ad libitum. The study included two experimental groups: (A) and (A+P), age matched to the older controls which received ad libitum Aronia melanocarpa juice (for group A) and Aronia melanocarpa with addition of 1% pectin (for group A+P). Juices were diluted 1:1 in drinking water. The experiment lasted 90 days [11]. The experimental protocol was approved by the Committee on Ethical Treatment of Animals from the Bulgarian Agency for Food Safety. At the end of the experimental period the animals were euthanized with T61. The rats of all groups were measured to establish body weight (g), thymus weight (g), thymus length and width (mm) and the thymus index (as organ weight(g)/weight of animal(g).100). After dissection and fixation in formalin, thymus sections were subjected to routine paraffin embedding, cutting and staining with hematoxylin and eosin. Tissue sections of 5  $\mu\text{m}$  thickness were incubated with a ready-to-use Bcl-2 (mouse antibody sc-509, Santa Cruz Biotechnology, Inc. USA) and visualizing kit “ABC Staining system” (sc-2017, Santa Cruz Biotechnology, Inc. USA). The enclosed photomicrographs were taken on microscope Nikon Microphot SA (Japan), equipped with a digital camera Camedia-5050Z (Olympus, Japan). The data were processed by non-parametric analysis (Kruskal-Wallis test) and multiple comparison analysis (Dunnett T3 test). Statistical significance between experimental groups was determined by u-criterion of Mann-Whitney, the differences were considered significant at  $p < 0.05$ . Data are presented as mean $\pm$ SD.

## Results

### Thymus Weight

The average weight of the thymus in the elderly controls and in both groups treated rats was significantly lower than in young controls (0.2133 g for group Co, 0.2450 g for group A and 0.2360 g for group A+P v/s 0.3471 g for group Cy;  $p < 0.05$ ), which is concordant with the chosen experimental model. There was a tendency to increase the weight of the thymus in the groups treated with Aronia only and Aronia and pectin compared to adult controls without statistically significant differences in the different values ( $p > 0.05$ ).

### Thymus length

The average length in young controls was significantly higher compared to old controls (18.00 mm for group Cy v/s 14.33mm for group Co;  $p < 0.05$ ) and compared to Aronia with pectin group (18.00 mm for group Cy v/s 15.60 mm for group A+P;  $p < 0.05$ ).

### Thymus width

The average width in young controls was significantly higher than old controls (14.00 mm for group Cy v/s 10.66 mm for group Co;  $p < 0.05$ ) and than Aronia with pectin group (14 mm for group Cy v/s 10.40 mm A+P for group;  $p < 0.05$ ).

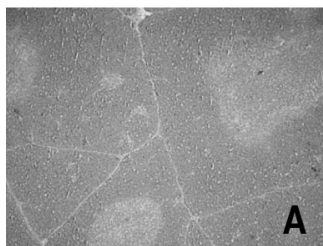
The average length and width of the thymus in the groups receiving Aronia and Aronia with pectin compared to adult controls tend to increase without statistically significant differences ( $p > 0.05$ ).

### Thymus weight index

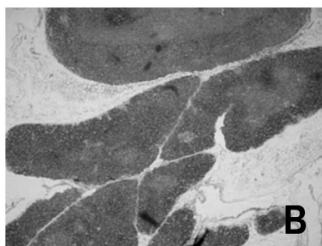
With respect to thymus weight index between young and old controls the differences were statistically significant, which confirms the process of age involution of the thymus. There was a statistically significant difference between the young controls compared to elderly controls (0.33 for group Cy v/s 0.61 for group Co;  $p < 0.05$ ) and between young controls in comparison to the two treated groups (0.33 for group Cy v/s 0.58 for group A and 0.58 for group A+P;  $p < 0.05$ ). No significant differences were found between the groups treated with Aronia juices compared to the old controls ( $p > 0.05$ ).

### Histology of rat thymus

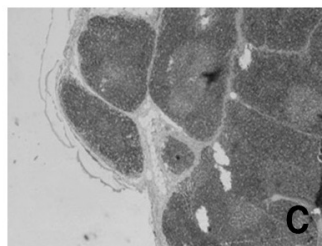
The thymus of young rats (2 months old) was characterized by oval thymic lobules with broad cortex area rich in thymocytes, clear and distinct cortico-medullary border, presence of medulla and outside thin capsule with interlobular loose connective tissue (**Fig. 1A**). At month 13 the controls show a marked decrease in the density of the



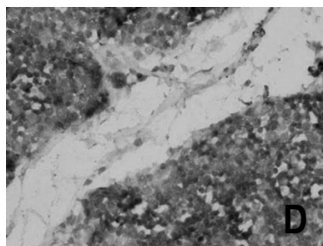
**Fig. 1A.** Thymus of 2-month-old rat, CY group (HE,  $\times 40$ )



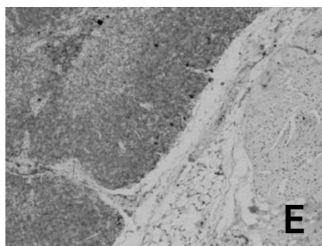
**Fig. 1B.** Thymus of 13-month-old rat, CO group (HE,  $\times 40$ )



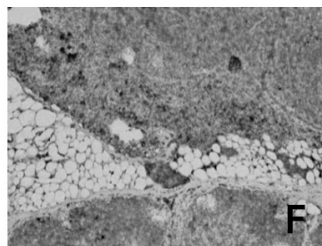
**Fig. 1C.** Thymus of 13-month-old rat, Aronia group (HE,  $\times 40$ )



**Fig. 1D.** Bcl-2, young controls ( $\times 100$ )



**Fig. 1E.** Bcl-2, old controls group ( $\times 40$ )



**Fig. 1F.** Bcl-2, Aronia and pectin group ( $\times 40$ )

thymocytes in the outer and inner cortical regions with thinning and sharpening of the lobules. The cortico-medullary border becomes obscure. Interlobular amount of connective and fatty tissue is increased, the thymus capsule is thickened (**Fig. 1B**). When comparing the older controls with treated with Aronia animals parallel to age-related changes is noticed an enhanced apoptosis, particularly in cortical areas, forming the characteristic picture of starry sky appearance (**Fig. 1C**). Vigorous apoptosis is represented both in Aronia and in Aronia and pectin treated rats.

### Immunohistochemistry

Young controls showed an increased immune expression of Bcl-2, as a feature of the normal physiological process of apoptosis (**Fig. 1D**). In the adult controls is noticed only weak and scattered immune expression of Bcl-2 (**Fig. 1E**). Both groups of treated animals was found strongly positive for Bcl-2 similar in intensity to that in younger controls (**Fig. 1F**).

### Discussion

Apoptosis is an essential physiological process during differentiation and maintenance of immune cells including the thymocytic population. Apoptosis in thymus can be induced by stimuli such as high dose of corticosteroids, gamma radiation, immunosuppressives and oxidants [1]. As some of the polyphenols, the predominant group bioactive substances in Aronia may have bidirectional effect – as anti- and pro-oxidants, which is dose dependent and ion specific [5]. Induction of apoptosis in lymphoid cells underlies their antitumoral effect, but in our case it refers to normal lymphoid cells [5]. The anti-apoptotic marker Bcl-2 is represented to its highest extend by the T lymphocytes at an early stage in their differentiation - the double negative T-cells stage, and also in their final stage – the double positive T-cells stage, as a sign of the active T lymphocytes proliferation in the young thymus [11]. The presence of increasing apoptosis and the simultaneous activation of the anti-apoptotic protein Bcl-2 of the treated animals suggests different hypotheses. On one hand, the enhanced apoptosis may be a result from pro-oxidant effect of Aronia melanocarpa and the higher immunoeexpression of Bcl-2 could be a result of a defense reaction to the first process. On the other hand, this apoptosis may come as a result of a thymus remodeling that has already began by losing its adult lymphocytes and activating a proliferation for producing new T lymphocytes at the same time. These results put many questions, the answers to which demand additional functional study of the thymus in the treated and untreated adult animals.

### References

1. **Burikhanov, R., K. Wakame, Y. Igarashi, S. Wang, S. Matsuzaki.** Suppressive effect of active hexose correlated compound (AHCC) on thymic apoptosis induced by dexamethasone in the rat. – *Endocr. Regul.*, **34**, 2000, 180-188.
2. **De la Fuente, M., J. Cruces, O. Hernandez, E. Ortega.** Strategies to improve the functions and redox state of the immune system in aged subjects. – *Curr. Pharm. Des.*, **17**, 2011, 3966-3993.
3. **Denev, P., Ch. Kratchanov, M. Ciz, A. Lojek, M. Kratchanova.** Bioavailability and antioxidant activity of black chokeberry (aronia melanocarpa) polyphenols: in vitro and in vivo evidences and possible mechanisms of action: a review. – *Compr. Rev. Food Sci. F.*, **11**, 2012, 472-489.
4. **Feng, R., H. Ni, S. Wang, I. Tourkova, M. Shurin, H. Harada, X. M. Yin.** Cyanidin-3-rutinoside, a natural polyphenol antioxidant selectively kills leukemic cells by induction of oxidative stress. – *J. Biol. Chem.*, **282**, 2007, 13468-13476.

5. **Halliwell, B.** Review: Are polyphenols antioxidants or pro-oxidants? What do we learn from cell culture and in vivo studies? – *Arch. Biochem. Biophys.*, **476**, 2008, 107-112.
6. **Lynch, H., G. Goldberg, A. Chidgey, M. van den Brink, S. Boyd, G. Sempowski.** Thymic involution and immune reconstitution. – *Trends. Immunol.*, **30**(7), 2009, 366-373.
7. **Mennen, L, I., R. Walker, C. Bennetau-Pelissero, A. Scalbert.** Risks and safety of polyphenol consumption. – *Am. J. Clin. Nutr.*, **81**(suppl), 2005, 326S-329S.
8. **Montecino-Rodriguez, E., B. Berent-Maoz, K. Dorshkind.** Causes, consequences, and reversal of immune system aging. – *J. Clin. Invest.*, **123**(3), 2013, 958-965.
9. **Obukhova, L., V. Skulachev, N. Kolosova.** Mitochondria-targeted antioxidant SkQ1 inhibits age-dependent involution of the thymus in normal and senescence-prone rats. – *Aging*, **1**, 2009, 389-401.
10. **Pećas-Solarović, B., V. Pesić, K. Radojević, G. Leposavić.** Morphometrical characteristics of age-associated changes in the thymus of old male Wistar rats. – *Anat. Histol. Embryol.*, **35**(6), 2006, 380-386.
11. **Renault, T., J. Chipuk.** Getting away with murder: how do the BCL-2 family of proteins kill with immunity? – *Ann. N.Y. Acad. Sci.*, **1285**(1), 2013, 59-79.
12. **Sharif, T., M. Alhosin, C. Auger, C. Minker, J. Kim, N. Selloum, P. Bories, H. Gronemeyer, A. Lobstein, C. Bronner, G. Fuhrmann, V. Schini-Kerth.** Aronia melanocarpa juice induces a redox-sensitive p73-related caspase 3-dependent apoptosis in human leukemia cells. – *Plos One*, **7**(3), 2012, 1-11.
13. **Балански, Р., Г. Ганчев, И. Стойчев, М. Илчева, А. Томова, П. Денев, М. Крачанова, Хр. Крачанов.** Ефект на натурален сок от Арония, обогатен с пектин върху канцерогенното действие на 1,2-диметилхидразин в интестиналния тракт на плъхове. – *Българско дружество по хранене и диететика*, **1**, 2008, 220–227.