

Anatomical Peculiarities and Morphometric Characteristics of the Intramural Part of Porcine Ureter

Nikolay Tsandev^{1}, Ivailo Stefanov², Genadi Kostadinov¹,
Angel Vodenicharov¹*

¹ *Department of Veterinary Anatomy, Histology and Embryology, Faculty of Veterinary Medicine, Trakia University, Stara Zagora, Bulgaria*

² *Department of Anatomy, Faculty of Medicine, Trakia University, Stara Zagora, Bulgaria*

* Corresponding author e-mail: drcandev@abv.bg

The intravesical part of porcine ureter from 100 (50 male and 50 female) six months, 95-105 b.w. Bulgarian White x Landrace pigs, slaughtered for a meat consumption in accordance with Bulgarian legislation, were studied after silicone filling, radiography and corrosion casts measuring. It was established that the intramural part showed a well expressed curved course (almost 90°) with laterally oriented arch and distension just before transmission into ureteric columns. The statistical data (presented as mean ± SD) of studied morphometric parameters on silicone replicas - diameter and length of both sides of that ureter's part and distance between two ureteral orifices (ostia ureterica), as well, showed little more values in females vs. males ones, with no statistical significance ($P > 0.05$, one-way ANOVA). Similarly, the diameter and length of right ureters were with little more values that these of left ones. Also, an asymmetry in ureteric ostia location was observed - 15.4% in males and 38.5% in females, with different position each toward other. Ureteric ectopy was not observed in all studied animals. The original data obtained add a species specific feature and could be useful also for medico-biological studies concerned to man and probably for a xenotransplantation.

Key words: ureter, intravesical part, anatomy, morphometry, pig

Introduction

The intramural part of the ureter, located in the bladder's wall, showed specific peculiarities and for this reason it has a special morphological, functional and clinical interest. Although the ureters penetrating the bladder's wall lose their smooth muscle cells, the remaining ureteric part retains as independent organ, situated dorsally into the bladder's wall. The remaining part of longitudinal smooth musculature does not fuse with those of the bladder, but it is attached to its wall [1, 2, 3, 6, 8, 16]. The intravesical part in domestic animal has different length, varying from several millimeters to 2-3 centimeters and depends mostly on the animal species. It is importantly that as in human, this part has an anatomical narrowing in which a urinary stones could be retained - sometimes provoking inflammation, leading to ureteric musculature spasm. As a result of a particular or full ureter obstruction a hydronephrosis or hydroureteronephrosis is developed

[2, 3, 4]. It is commonly accepted that the oblique situation of ureters into the bladder's musculature, narrowing lumen, muscle cells contraction and pressure of the urine on bladder's wall are factors which prevent urine reflux into the ureter from filled bladder and contraction of its wall [3, 5, 6, 8, 16]

The intravesical part of the ureter and respective area of the bladder form the ureterovesical junction which allows unhindered passage of urine from the ureter to the bladder while preventing the reflux [15, 17]. Comparative study of Shehata [16] on eleven mammalian species showed some differences in the intramural portion of the ureter concerning to submucous ureter, three types of that ureteral part and gender peculiarities in the muscular pattern of both ureter and urinary bladder.

With respect to anti-reflux mechanism of ureterovesical junction the juxta- and intravesical ureter and its relationship to the surrounding musculature have been studied by enzyme histochemistry in pig [15] and in human [10]. The data obtained showed that the ureter orifices are macroscopically located approximately the bladder neck in pig, the porcine trigone is less developed compared to that in human and is located very close to the dorsal aspect of the bladder neck. Also, an enzyme histochemical study revealed a lack of periureteric muscle sheet in pig [10].

Obtaining a complete draft of the pig genome sequence has been central to the development and broad acceptance of the pig as a biomedical model [9, 11, 12, 14].

The absence of data about the direction and running as well as measurements of intravesical part of porcine male and female ureters and increasing importance of pig as model in biomedical research motivated us to perform this study.

Materials and Methods

Animals: The intravesical ureteric part with adjacent area of the bladder from 100 (50 male and 50 female), 6 months old, 95-105 b.w., cross-breeding Bulgarian White and Landrace pigs were collected for this study. The animals were slaughtered for meat consumption in licensed abattoir in accordance with the Bulgarian legislation.

Experimental design: The pelvic parts of the ureters together with whole urinary bladder were carefully removed from the corps immediately after animal slaughtering. After 24 h staying at 40°C in refrigerator they were filled with silicone elastomer (Elite Double 22, Zhermack, BadiaPolesine, Italy), acryl acrylate resin (Duracryl, Spofa Dental, Praha, Czech Republic) and saturated solution of lead tetroxide in 10% water solution of gelatin. In order to fill the specimens with polymerized matter, following respective procedures were used: dissection (silicone elastomer), corrosion in 10% KOH (acrylate resin) and R \ddot{o} graphy (saturated liquid of lead tetroxide (**PbO₄**) in 10% water gelatin). Only silicone replicas with visible longitudinal grooves and gyri (reflecting the relief of ureteral mucosa) were used for metric evaluations.

The measures were carried out only on silicone replicas with visible longitudinal grooves and gyri using digital caliper and obtained data were processed using GraphPad Prism 6 for Windows (GraphPad Software, Inc., USA) via one-way analysis of variance (one-way ANOVA). P-values <0.05 were considered statistically significant. The data are presented as mean \pm SD.

Results and Discussion

The observations after dissection, as well as on silicone replicas, corrosion casts and R \ddot{o} grams showed that intravesical part of the ureter has a well expressed course (almost 90°) into the urinary bladder wall with laterally oriented arch. A distension just before

transmission of ureter (juxtavesical ureteral part) into urinary bladder's wall followed by distention within the wall, were also found (**Fig. 1a, b**).

The morphometric measurements of both right and left ureter replicas diameter, length and distance between two ostia (right and left ostium ureteris) of each studied animal, and asymmetry between the ostia are given on **Table 1**. The data presented showed that as a whole the values of diameter and the length of intramural part silicone replicas in female individuals were higher than in male animals. This fact is difficult to explain, but it could be presume that at that age female pigs are a little more mature than males. The asymmetry between ostia was also found more often in females than in males - 38.5% vs. 15.4%, respectively. Our results about the ostia location asymmetry confirm in part the data of [7] on human ureters where almost all cases with asymmetry were observed in females, and only one in male individuals.

No statistical significance differences were established between studied parameters.

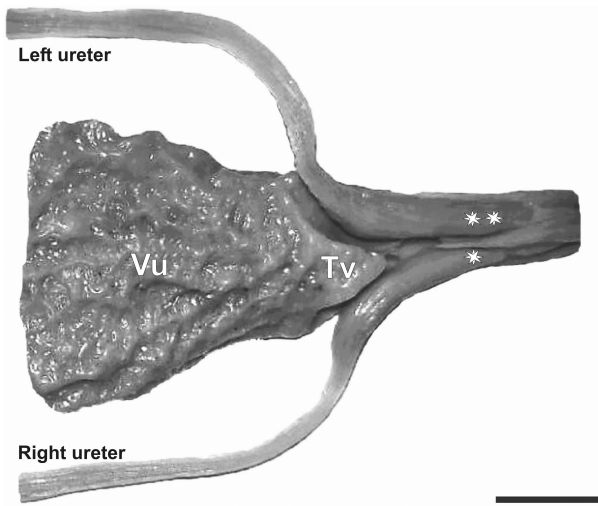


Fig. 1a. Silicone replica of bladder and asymmetry (*, **) of ureters in female pigs. **Tv**-trigonum vesicae; **Vu**-vesicaurinaria; Bar = 1 cm

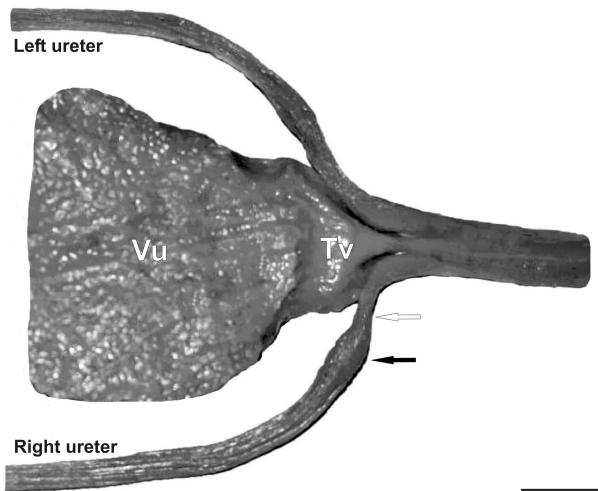


Fig. 1b. Silicone replica of bladder and ureters in female pigs. Silicone replica of bladder and ureters in male pigs. **Tv**-trigonim vesicae; **Vu**-vesical urinaria; enlargement (black arrow) and distention (white arrow) in terminal part of ureter. Bar = 1 cm.

Table 1. Measurements of intramural part of ureters and percentage of ostia location asymmetry between male and female pigs

PARAMETERS	MALES	FEMALES
SILICONE CASTS OF THE URETER INTRAMURAL PART Diameter Right Left	2.68±1.55 2.19±0.73	3.02±0.91 2.79±1.10
SILICONE CASTS OF THE URETER INTRAMURAL PART Length Right Left	10.60±2.41 9.85±1.84	12.86±3.93 11.75±3.79
OSTIUM URETERIS Distance between the two ostia	2.53±1.07	3.65±0.95
OSTIUM URETERIS Percentage of asymmetry	15.4% (7.7% - right ostium localized behind the left one; 7.7% - left ostium localized behind the the right one)	38.5 % (23.1% - right ostium localized behind the left one; 15.4% - left ostium localized behind the the right one)

Conclusion

The original data obtained about the course, diameter, length of intramural part silicone replicas, distance between the ureteric ostia and percentage of asymmetry in both male and female individuals add the knowledge for ureter anatomy peculiarities in this animal species. Our results could be useful in biomedical researches in relation of man, veterinary clinical practice as well as in further studies concerning xenotransplantation where domestic pig are involved as suitable animal model.

References

1. Arrabal-Martin, M., A. Zuluaga-Gomez, S. Merino-Salas, M. Noguerras-Ocacia, M. A. Arrabal-Polo. Endoscopic treatment of ureterovesical junction obstructive pathology: A description of the oblique meatotomy technique and results. - *Can. Urol. Assoc. J.*, 7(11-12), 2013, 728-731.
2. Barone, R. Comparative anatomy of domestic mammals. Vol. 4, Vigot, Paris, 2001, 46-61. [in French]
3. Chouchkov, H., W. Ovtcharoff, N. Stoinov. *Clinical Anatomy*, 1995, 335-358.
4. Dyce, K. M., W. O. Sack, C. J. G. Wensing. Textbook of veterinary anatomy. St. Louis, Missouri, Saunders Elsevier, 4th ed., 2010, 181-184.

5. **Goessl, C., Z. Grozdanovic, H. H. Knispel, H. E. H. Wegner, K. Miller.** Nitroergic innervation of the human ureterovesical junction. - *Urol. Res.*, **23**, 1995, 189-192.
6. **Ham, A. W., D. H. Cotrmack.** Histology. (Russ. ed.) Moscow, Mir, 1983, Vol. 5, 41-45.
7. **Kabakian, H. A., H. K. Armenian, Z. L. Deeb, G. K. Rizk.** Asymmetry of the pelvic ureters in normal females. - *Am. J. Roentgenol.*, **127**, 1976, 723-727.
8. **Köning, H. E., J. Maierl, H.-G. Liebich.** Urinary system (Organa urinaria). - In: *Veterinary anatomy of domestic animals* (Eds. H. E. Köning and H.-G. Liebich), Stuttgart, Schattauer, 2004, 375-378.
9. **Kuzmuk, K. N., L. B. Schook.** Pigs as model in biomedical science. - In: *The Genetic of the pig* (Eds. M. F. Rothschild, A. Ruvinsky), CAB International, 2011; 426-444.
10. **Roshani, H., N. F. Dabhoiwala, F. J. Verbeek, W. H. Lamers.** Functional anatomy of the human ureterovesical junction. - *Anat. Rec.*, **245**, 1996, 645-651.
11. **Schook, L. B., J. E. Beever, J. Roger, S. Humphray, A. Archibald, P. Chardon, D. Milan, G. Rohrer, K. Eversole.** Swine genome sequencing consortium (SGSC): a strategic roadmap for sequencing the pig genome. - *Comp. Funct. Genom.*, **6**, 2005a, 251-255.
12. **Schook, L. B., C. Beattie, J. E. Beever, S. Donovan, R. Jamison, F. Zuckermann, S. Niemi, M. Rothschild, M. Rutherford, D. Smith.** Swine in biomedical research: creating the building blocks of animal models. - *Anim. Biotech.*, **16**, 2005b, 183-190.
13. **Shehata, R.** A comparative study of the urinary bladder and the intramural portion of the ureter. - *Acta Anat.* **98**, 1977, 380-395.
14. **Swindle, M. M., A. Makin, A. J. Herron, F. J. Clubb, K. S. Frazier.** Swine as models in biomedical-research and toxicology testing. - *Vet. Pathol.*, **49**, 2012, 344-356. DOI: 10.1177/0300985811402846
15. **Thomson, A. S., N. F. Dabhoiwala, F. J. Verbeek, W. H. Lamers.** The functional anatomy of the ureterovesical junction. - *Brit. J. Urol.*, **73**, 1994, 284-291.
16. **Vankov, V., W. Ovtcharoff.** Anatomy of the Man. Sofia, Arso, 10th ed., 337-343.
17. **Vernet, S. G.** Anatomical aspects of vesicoureteral reflux. - In: *Urodynamics upper and lower urinary tract* (Eds. W. Lutzeyer, H. Meldeior,), Springer-Verlag Berlin Heidelberg, 1973, 171-178.