

HIV-Associated Sarcoma Kaposi in an Athlete

Valentin Valtchev¹, Mary Gantcheva^{2*}

¹ Department of Physiology and Biochemistry, National Sports Academy, Sofia, Bulgaria

² Institute of Experimental Morphology, Pathology and Anthropology,
Bulgarian Academy of Sciences, Sofia, Bulgaria

Corresponding author: e-mail mary_gant@yahoo.com

We present a case of a 26-year-old homosexual male, an athlete, diagnosed with a HIV-associated Kaposi's sarcoma. We want to point that HIV is worldwide infection, also seen in Bulgaria and to stress that Kaposi's sarcoma is one of the leading signs of AIDS.

Key words: Kaposi's sarcoma, HIV- infection

Introduction

The acquired immunodeficiency syndrome (AIDS) affects vast groups of individuals around the world. AIDS is a disease of the human immune system, caused by the human immunodeficiency virus (HIV). The illness decreases the effectiveness of the immune system, which leads to opportunistic infections. People with AIDS are also in higher risk of developing different types of cancer, such as Kaposi's sarcoma and lymphomas. Other symptoms of the disease include fever, sweating, swollen glands, fatigue and weight loss [4, 5, 7].

AIDS has been discovered as an illness for the first time in 1981 in New York. AIDS is one of the most dangerous viral diseases known to humankind. Nowadays, it is the leading cause of death for active-age individuals. Over 33 million people around the world carry the HIV virus; every 12 seconds a person gets infected, and every 16 seconds someone dies from AIDS. In Bulgaria, the number of people carrying the virus is 4 thousand, 3 thousand of which live unaware of the fact. Half of the infected in the country are under 30 years old [10].

Kaposi described in 1872 a case as a malignant multifocal neoplastic process, arising from the endothelium of the vascular and the lymph vessels [1, 3, 4]. In about 30% of the patients suffering from AIDS, Kaposi sarcoma is an initial dermal manifestation of the disease. In these cases, the dermal lesions are different from the classic Kaposi sarcoma type. They are smaller in size, localized mainly in the upper part of the torso and the oral mucosa, and the progress is faster. Internal organs are affected in 75% of the cases [1, 2, 3]

Stages of the HIV infection: The *first stage*, or the primary HIV infection, also known as an "acute retroviral syndrome", develops in the first few weeks after con-

tracting the HIV virus. It is characterised by symptoms similar to those of the flu or the infectious mononucleosis that often go away after a couple of weeks [2]. The *second stage* is known as the “clinical latency” one, when the HIV virus progressively destroys its CD4 T-lymphocytes, while the patient shows no symptoms. This condition can remain for an average period of 8 to 10 years [1]. The *third stage* occurs when the immune system is so badly damaged, that it starts developing opportunistic infections. This exact stage is called AIDS. “A person with AIDS” refers to an individual infected with the HIV virus, whose blood contains less than 200 CD4 T-lymphocytes per microliter, and who suffers from one or more of 26 given conditions. For people with AIDS the opportunistic infections are often extremely grave and life-threatening [10]. The worldwide spread of the HIV pandemic is taking alarming proportions. The number of people living with HIV around the globe is constantly growing, as well as the death rate among them. The lack of a cure for the disease is beneficial for its spread. There is a need of serious prevention measures to control the epidemy.

Transmission of the HIV virus: HIV is transmitted through sexual contact, par-enteral transfusion of blood and blood components, contamination of wounds or the mucous with infected blood or from a mother with HIV to her new-born [6, 8, 9].

Case report

We present a case of a 26-year-old homosexual male, who is an active athlete. The patient has visited a training camp in the Netherlands in 2013, where he had a couple of sexual encounters without using prevention methods. He was diagnosed as HIV(+) in 2014 in Sofia, with initial symptoms of swollen inguinal lymph nodes. He lost 8 kilograms for 6 months. Pathologic changes in the derma occurred with livid erythematous macules and plaques on the hard palate mucous membrane.

No abnormal digressions in routine paraclinical test results have been observed. Reported lower levels of CD4 + 133kn/ μ l. Serological detection of syphilis scored negative. The histopathological examination of a biopsy sample from the hard palate revealed vascular formations with predominance of endothelial cells and spindle-shaped cell formations with vascular slits, vasodilatation with extravasates and inflammatory perivascular dermal infiltrate- Sarcoma Kaposi (**Fig. 1** and **Fig. 2**).

The patient is a male of apparent age higher than the actual, asthenic habitus, pale skin and mucous. He has a rhythmic cardiac activity, AP – 110/70, cardiac frequency – 83 beats/minute, clean vesical breathing, painless abdominal palpation and no swelling of the joints. Body weight – 55kg. BMI -15.

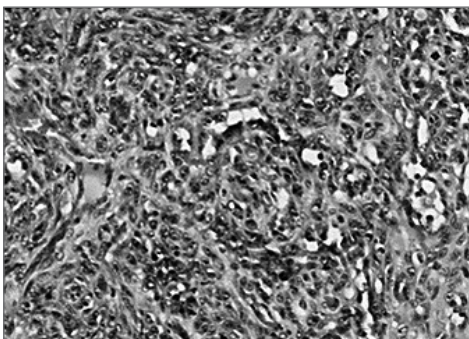


Fig. 1. Vascular formations with predominance of endothelial cells and spindle-shaped cell formations with vascular slits (HE, \times 200)

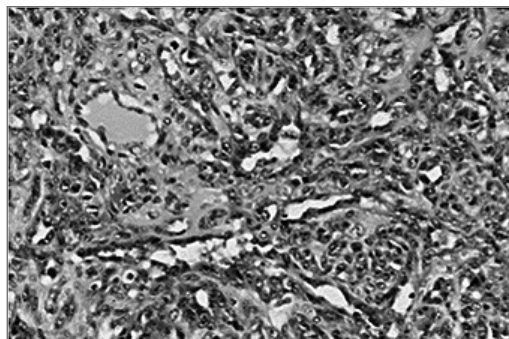


Fig. 2. Vasodilatation with extravasates and inflammatory perivascular dermal infiltrate (HE, \times 200)

Discussion

International Health Organisation Criteria for clinically-manifested HIV infections in adults:

1. Major feature: Sarcoma Kaposi; Candidiasis; Pneumonia (*Pneumocystis carinii*); Retinitis (Cytomegalovirus); Encephalitis;
2. Characteristic features: Hair Leucoplakia; Herpes zoster; B-cell lymphoma; Tuberculosis;
3. Disease-related features: Genital ulcers; Loss of weight; Lymphonodulomegaly; Diarrhea; Cough.

According to the criteria of the International Health Organisation for clinically manifested HIV infections in adults, there were two major features present in our patient - Kaposi sarcoma and candidiasis. Some of other HIV-related characteristics include B-cell lymphoma; while three disease-related symptoms are manifested by genital ulcers, loss of weight and lymphadenomegaly.

It is agreed that a person has a clinically-manifested HIV infection if clinical testing detects:

1. At least one major feature;
2. At least two characteristic features;
3. One characteristic and at least two related features;
4. Two related features along with a HIV positive test.

Our patient has been diagnosed with one major feature - Sarcoma Kaposi and two disease-related features (loss of weight and lymphonodulomegaly).

Diagnosis: On the basis of data from the history, clinical presentation and laboratory findings, it was concluded that the patient had HIV-associated Kaposi sarcoma.

In conclusion, the patient we presented has a HIV-associated Kaposi sarcoma.

References

1. **Engels, E., R. Biggar, H. I. Hall, H. Cross, A. Crutchfield, J. L. Finch, R. Grigg, T. Hylton, K. S. Pawlish, T. S. McNeel, J. J. Goedert.** Cancer risk in people infected with human immunodeficiency virus in the United States. – *Int. J. Cancer*, **123**(1), 2008, 187-194.
2. **Feller, A., T. Flanigan.** HIV-infected competitive athletes. What are the risks? What precautions should be taken? – *J. Gen. Intern. Med.*, **12**(4), 1997, 243-246.
3. **Feller, L., C. Anagnostopoulos, N. H. Wood, M. Bouckaert, E. J. Raubenheimer, J. Lemmer.** Human immunodeficiency virus-associated Kaposi sarcoma as an immune reconstitution inflammatory syndrome: a literature review and case report. – *J. Periodontol.*, **79**(2), 2008, 362-368.
4. **Kaviarasan, P. K., T. J. Jaisankar, D. M. Thappa, S. Sujatha.** Clinical variations in dermatophytosis in HIV infected patients. – *Indian J. Dermatol. Venereol. Leprol.*, **68**(4), 2002, 213-216.
5. **Zancanaro, P. C., L.Y. McGirt, A. J. Mamelak, R. H. Nguyen, C. R. Martins.** Cutaneous manifestations of HIV in the era of highly active antiretroviral therapy: An institutional urban clinic experience. – *J. Am. Acad. Dermatol.*, **54**(4), 2006, 581-588.
6. **Rigopoulos, D., V. Papanizos, A. Katsambas.** Cutaneous markers of the HIV infection. – *Clinics in Dermatology*, **22**(6), 2004, 487-498.
7. **Regional Health Inspection, Veliko Tarnovo,** <http://www.riokoz-vt.com/aids.htm>. [in Bulgarian].
8. **Sackoff, J. E., D. B. Hanna, M. R. Pfeiffer, L. V. Torian.** Causes of death among persons with AIDS in the era of highly active antiretroviral therapy. – *Ann. Intern. Med.*, **145**(6), 2006, 397-406.
9. **Sentamilselvi, G., A. Kamalam, K. Ajithandas, C. Janaki.** Dermatophytosis and human immunodeficiency virus (HIV) infection. – *Indian J. Dermatol.*, **43**, 1998, 10-12.
10. **Staughton, R.** Skin manifestations in AIDS patients. – *Br. J. Clin. Pract. Suppl.*, **71**, 1990, 109-113.