

## NOS positive mast cells in the pelvic urethra of male pigs

*G. Kostadinov, A. Vodenicharov, I. Stefanov, N. Tsandev*

*Department of Veterinary Anatomy, Histology and Embryology, Faculty of Veterinary Medicine, Trakia University, 6000 Stara Zagora, Bulgaria*

With regard to our thorough research on mast cells in the pelvic urethra of male pigs, the aim of the present study was to obtain more data about the histochemical features of these cells by finding out whether they were positive for nitric oxide. The incentive of the study was the key role of nitric oxide (NO) and the closely related isoenzymes of nitric oxide synthase for a number of physiological and pathological events in the animal body. The study of NOS would also contribute to obtaining more information for the innervation of the organ in this animal species.

*Key words:* nitric oxide (NO), mast cells, pelvic urethra, pig.

### Introduction

It is known that nitric oxide synthases (NOS) are haemoproteins which catalyse the oxidation of L-arginine and L-citrulline to nitric oxide. The synthesis of its isoenzymes is regulated by specific genes. Three isoforms are known, two of which are cell-bound – the neuronal and endothelial (nNOS and eNOS) and the third – free (iNOS). All three NOS are used as diagnostic markers of various vascular disorders, pathological deviations in the function of endocrine and exocrine glands (Quesada et al. 2002). NOS expression was established by Kawamoto et al. (1998) in the epithelium of human nasal mucosa, nasal glands, nerve fibres and the endothelium. Persson et al. (1998) assayed the possible co-presence of nitric oxide (NO) and acetylcholine in the major pelvic ganglia in rats by immunohistochemistry with antiserum against NO and acetylcholine esterase (AChE). Data from similar studies in the urethra of female pigs have demonstrated the presence of nitrenergic, peptidergic and acetylcholine esterase-positive nerves in its distal part. Further, immunoreactivity to catecholamines containing various peptides, as well as immunoreactive nerves were established in the muscle layers of the urethra, in the propria, ureter and near the blood vessels (Crowe et al. 1989, Persson et al. 1995, Vodenicharov et al. 2005).

The important role of nitric oxide for a number of physiological and pathological events in the animal body, and the lack of data about NOS-positive mast cells in the pelvic urethra of domestic pigs motivated the present study aimed at completing the available information about the histochemical features of mast cells and the innervation of this organ in pigs.

## Material and Methods

The specimens (pelvic urethras) were obtained from 12 healthy male Belgian Landrace pigs, 6–8 months of age, weighing 90–110 kg, slaughtered at the licensed slaughterhouse for a meat consumption of Dimes 2000 Ltd in compliance with all Bulgarian legislative norms. Immediately after the slaughter, the material was fixed by immersion in 10 % neutral formaldehyde (Merck, Darmstadt, Germany) for 48h. Further, the material was dehydrated in ascending ethanol series, cleared in xylene and embedded in paraffin. Cuts 5-6  $\mu\text{m}$  thick were treated according to the routine ABC-HRP method with antigen unmasking in 0.01 M citrate buffer, pH 6.0 (Atanassova et al. 2005). Initially, they were treated with 3% (v:v) hydrogen peroxide ( $\text{H}_2\text{O}_2$ ) in methanol and then, blocked with Normal Swine Serum with 5% BSA (Sigma Chemical A3425, St Louis, MO, USA). The primary universal antibody – rabbit anti-nitric oxide synthase universal (N-217, Sigma-Aldrich, Chemie GmbH, Germany) for detection of the three NOS isoforms: neuronal, endothelial and inducible; was applied diluted 1:100 overnight at 4°C. The subsequent incubation was done with Swine Antirabbit Biotinylated IgG (DAKO E0353 Glostrup, Denmark) and ABC-HRP (DAKO; K0355, Glostrup, Denmark). The reaction was developed with DAB (liquid DAB+Substrate-Chromogen System) (DAKO; K3468, Glostrup, Denmark) and controlled under microscope, and afterwards was stopped in water. Then followed contrast staining with Harris' haematoxylin, dehydration and covering with Pertex mounting medium (CellPath plc). Negative controls were run without the primary antibody or after preabsorption with immunogenic peptide at a ratio of 1:10.

## Results and Discussion

The light microscopy demonstrated expression of nitric oxide synthase in almost all structures of the pelvic urethral wall. In mucosal epithelial cells, positive expression was observed only in the cytoplasm, but not in the nuclei (Fig. 1).

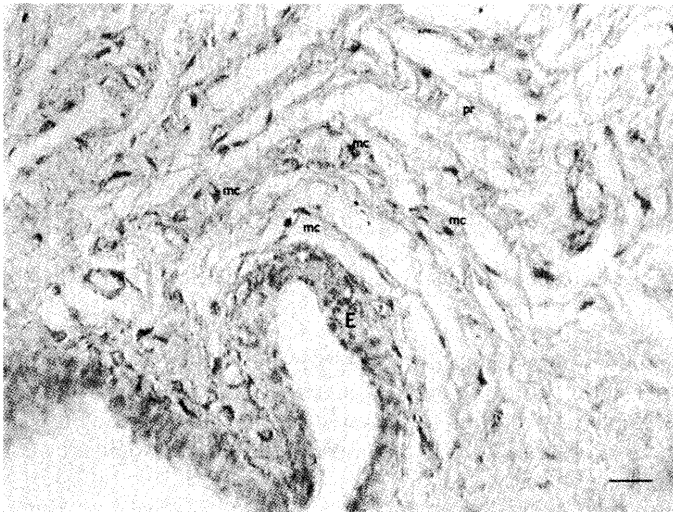


Fig. 1. Expression of nitric oxide synthase in epithelial cells (E) of the mucosa, as well as in mast cells (mc), located into the propria (pr). Bar = 20  $\mu\text{m}$ .

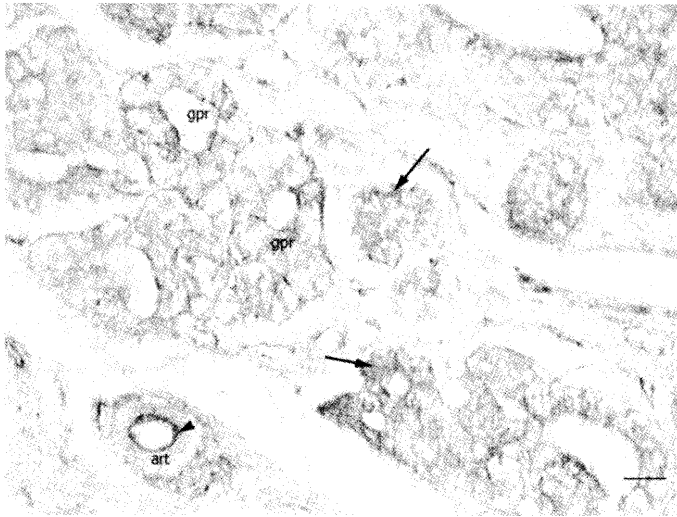


Fig. 2. Positive reaction in secretory cells (arrows) of glands (gpr), and in the endothelium (arrowhead) of the arteriole (art). Bar = 20  $\mu$ m.

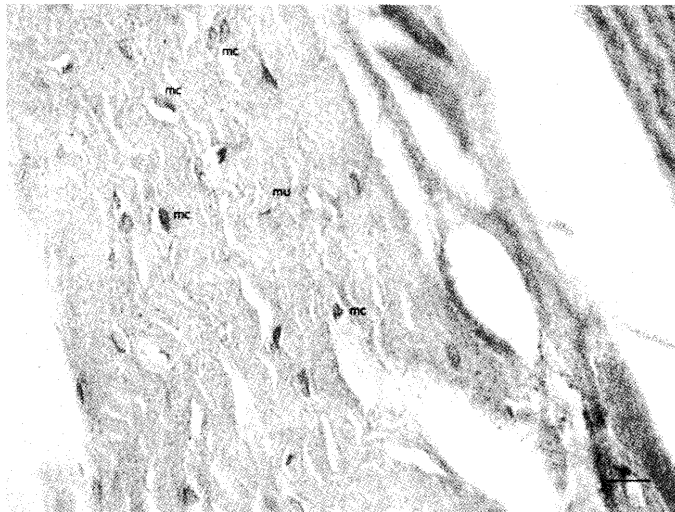


Fig. 3. Positive reaction in the cytoplasm of muscle cells (mu).

Immunohistochemical reactivity was observed also in secretory cells of glandular lobules of the prostate. From the studied arteries and veins of a various calibers, the strongest expression was observed in the endothelium of arteries (Fig. 2).

A well expressed reactivity was also observed in the cytoplasm of striated muscle cells of *M. urethralis* (Fig. 3).

Localisation of NOS-positive mast cells in *M. urethralis* (mu). Bar = 20  $\mu$ m.

The presence of NOS-positive mast cells was also detected in the different layers of the pelvic urethra. These cells were observed in the propria, mainly in vicinity of

vessels from the microcirculatory vascular bed and near the organ's epithelium. Some mast cells were found out around the urethral glands. NOS-positive mast cells were also found in the connective tissue layers of *M. urethralis*. NOS expression was demonstrated in small and larger blood vessels, located in the urethral muscle and the connective tissue of the pelvic urethra. The strongest expression was detected in intimal endothelial cells, and a less strong one – in the adventitia. There were also numerous NOS-positive mast cells in the perimysium, among the muscle cells. Our findings are in agreements with data reported in female pigs and guinea pigs (Crowe et al. 1989, Werkstrom et al. 1998). In our experiment, NOS reactivity was also exhibited by the glandular epithelium of the disseminate part of the prostate gland and its excretory ducts. The reacted epithelial cells of the excretory ducts outlined clearly the pattern of their arrangement and their direction towards the urethral lumen.

In conclusion, the presented data allowed supporting the opinion of some researchers about the importance of investigating the distal urinary tract and the innervation patterns of *M. urethralis* and the pelvic urethra, as the domestic pig is an appropriate experimental model for studying pathological alterations in men. The results could be used in patients with complications following surgery of the urinary bladder or the urethra or after vertebral column injuries.

## References

1. Barret, K., F. Pearce. Mast cells heterogeneity. – In: Immunopharmacology of mast cells and basophils, K. Barret and F. Pearce, eds., London: Academic Press, 1993, 29–38.
2. Crowe, R., G. Burnstock. A histochemical and immunohistochemical study of the autonomic innervation of the lower urinary tract of the female pig. Is the pig a good model for the human bladder and urethra? – *Journal of Urology*, 141, 1989, 414 – 422.
3. Kawamoto, A. H., C. T. Kello, R. Jones, K. Bame. Initial phoneme versus whole word criterion to initiate pronunciation: Evidence based on response latency and initial phoneme duration. – *Journal of Experimental Psychology: Learning, Memory, and Cognition*, 24, 1998, 862- 885.
4. Persson K., P. Alm, K. Johansson, B. Larsson, K. E. Andersson. Co-existence of nitregergic, peptidergic and acetylcholinesterase-positive nerves in the pig lower urinary tract. – *Journal of the Autonomic Nervous System* 52, 1995, 225 – 236
5. Persson K., P. Alm, B. Uvellius, K. E. Andersson. Nitregergic and cholinergic innervation of the rat lower urinary tract after pelvic gangliectomy. – *American Journal Physiology* 274, 1998, 389 – 397
6. Quesada, A., J. Sainz, R. Wangersteen, I. Rodriguez – Gomez, F. Vargas, A. Osuna, Nitric oxide synthase activity in hyperthyroid and hypothyroid rats. – *European Journal of Endocrinology*, 147, 2002, 117-122.
7. Vodnicharov, A., R. Leiser, M. Gulubova, T. Vlaykova, Morphological and Immunocytochemical investigations on mast cells in porcine ureter. – *Anatomia Histologia Embriologia*, 34, 2005, 343–349.
8. Werkstrom V., P. Alm, K. Persson, K.E. Andersson. Inhibitory innervation of the guinea-pig urethra; roles of CO, NO and VIP. – *Journal of the Autonomic Nervous System* 74, 1998, 33 – 42